

Single Stage Correction of Spinal Deformity Caused by a Hemivertebra Using a Transpedicular Approach

IOAN-CRISTIAN STOICA, ALEXANDRU DRĂGHICI
Carol Davila University of Medicine and Pharmacy
8 Eroilor Sanitari Blvd, Bucharest
ROMANIA
stoicacristianoan@gmail.com

Abstract - Congenital scoliosis is the most common congenital deformity, usually caused by one or more hemivertebra. There is strong progressive potential of the deformity in about 50% of scoliosis patients with this aetiology. The objective of our study was to report the results of the technique we use in the correction of congenital scoliosis caused by a hemivertebra and to determine the correction percentage of the deformity and observe the evolution in time of our patients. We selected a small study group of patients from our hospital, with complete medical records, with at least one year follow-up after the surgery, no other surgeries on that site and operated by the same senior surgeon. The technique we describe consists of a single approach procedure using transpedicular enucleation of the vertebra, removal of the pedicle, correction of the deformity and posterior fusion using segmentary fixation. The patient's mean age at the time of surgery was 14.78(\pm 2.09) years showing a progressive curve in the last year or a major deformity requiring surgical treatment; the mean scoliotic deformity was 62.35° (\pm 12.91) before surgery and 26.64° (\pm 11.57) after the operation; with a mean correction of 58.7(\pm 12.25)% of the initial curve. At the latest follow-up the mean curve was 28° (\pm 11.78), with no significant difference to the immediate postoperative measurement. Transpedicular enucleation associated with posterior spinal fusion is a safe and effective method for one-stage correction of a spinal deformity caused by the presence of a hemivertebra.

Key-Words: - Hemivertebra, Congenital, Scoliosis, Resection, Correction, Spinal Deformity

1 Introduction

Congenital scoliosis is the most common congenital deformity, most usually caused by the existence of one or more hemivertebra. Failure of formation or segmentation and a combination of these are the causes of congenital scoliosis. The hemivertebra is caused by complete failure of formation – missing one pedicle and a region of the vertebral body; incomplete failure leads to a wedged vertebra [1]. There is a strong progressive potential and little response to bracing treatment in the case of a patient with congenital scoliosis caused by a hemivertebra, the worst prognosis being in the fully segmented unincarcerated vertebra [1].

It is believed that congenital scoliosis is caused by damage caused to the fetus in the interval between the 5th and the 8th week of pregnancy (the spine development interval). It is also frequently associated with spinal cord dysraphism, congenital heart disease and kidney disorders [2].

Clinical examination of a patient presenting with a congenital scoliosis must be thorough, with focus on the skin of the patient, looking for the presence of nevi, hairy patches or hemangiomas which are signs

of a spinal dysraphism and on the cervical region due to the connection with the Klippel-Feil syndrome [3].

After we studied the literature and the statistics we observed that 25% of the curves do not progress, 25% progress in a moderate way and 50% progress very fast and need special treatment [4].

Surgical treatment of hemivertebra has been first described by Royle in 1921 [5], ever since there has been a large number of procedures that have been described, mostly based on the transpedicular approach and partial or complete removal of vertebral body [6].

In this paper, we shall describe the method we use, which consists of the enucleation of the vertebral body using a transpedicular access, somehow similar to the procedure used during a pedicle subtraction osteotomy [7], followed by the removal of the pedicle and a compression force applied on the vertebral segmentary stabilization system inserted.

2 Patients and methods

In this retrospective study, we reviewed all the medical records of the patients with a congenital scoliosis secondary to a hemivertebra, that were operated in the Foisor Hospital – in the interval 2007-2016, and we selected a small group of 14 patients with full medical records including the postoperative follow-up of at least 12 months, with no previous surgery on that area and operated by the same senior surgeon.

Our study was approved by the Hospital Ethics Committee and Review Board, all the patients and their legal representatives signed the informed consent the day before the surgery for the procedure.

The surgeries were performed by the same team, the patient placed in prone position on the radiolucent operating table, using endotracheal anesthesia and our surgeon-directed neuromonitoring system using motor evoked potentials for the patients operated in the final 4 years of the interval and the Stagnara wake-up test for the previous period [8].

We use a single approach procedure consisting of transpedicular enucleation of the vertebra, removal of the pedicle, correction of the deformity and a posterior fusion using segmentary fixation. The procedure starts with a posterior midline incision, subperiosteally dissection (extended to the lateral margin of the transverse process in the lumbar spine or to the proximal part of the rib in the thoracic spine) exposing the posterior elements at the level of the hemivertebra, and the levels above and below used for fixation. Pedicle screws are inserted above and below the hemivertebra level, according to our preoperative planning, to obtain the desired correction (because our patients have a Risser score of at least +++ we use a posterior final fusion technique). After having the intraoperative confirmation of the hemivertebra and the correct placement of the screws for the final correction we identify the posterior elements of the hemivertebra, remove the lamina if present resect any part of articular process if it exists, and open the pedicle with a probe. We use the pedicle canal to remove cancellous bone from the vertebral body with curettes, a technique similar to the one used in the pedicle subtraction osteotomy, after this the whole pedicle is removed. In case of a thoracic vertebra we usually resect the head of the rib articulated with the hemivertebra to allow better deformity correction; the rods are placed and the deformity is completely corrected using compression and distraction manoeuvres on the two rods [9]. If the patient's spine allows deformity satisfactory correction without complete removal of the hemivertebra's pedicle, we chose incomplete removal. We used the removed

cancellous and cortical bone as autologous bone graft and placed it on the lateral side of the rods to enhance formation of the arthrodesis.

One patient presented 3 months after surgery with 2 level screw pull-out, the surgery was revised, larger diameter screws were implanted and the fixation was extended with two levels; due to difficult cooperation with the patient we also used thoracolumbosacral brace for 3 months after the revision.

The preoperative evaluation of the patient consisted of standard blood tests, respiratory and neurologic evaluation, MRI examination (usually of the entire spine, looking for any abnormality of the spinal cord) and radiologic evaluation consisting of standing AP(antero-posterior) and LL(latero-lateral) x-rays of the whole spine and lateral-bending x-rays used for assessing whether the curves are structural or not. Cobb angles were measured according to the scoliotic curvature on AP view x-rays and standard sagittal balance measurements were made on the LL view (T4-T12 thoracic kyphosis, L1-S1 lumbar lordosis, the C7 plumb line and spino-pelvic parameters) – allowing us to determine also the sagittal imbalance of the patient before the surgery, if it was present, and the ideal kyphotic and lordotic curves for each case [10] [11]. All the patients had x-rays taken the first day after the surgery and standing ones taken at the usual follow-ups (6 week after the surgery, 3 months, 6 months, 1 year and then once per year).

3 Results

The 14 patient's ages were between 12-18 years (mean age 14.78 ± 2.09 years); 5 males and 9 females; with a follow-up period of 12-108 months (mean average follow-up 60 months). The mean preoperative scoliosis curve was $62.35^\circ (\pm 12.91)$ and the was corrected to a mean postoperative angle of $26.64^\circ (\pm 11.57)$, at the final recorded follow-up the mean Cobb angle was $28^\circ (\pm 11.78)$, – with no significant difference to the postoperative value ($P > 0.05$) -Table 1 thus showing the maintaining of the correction. The mean correction was 58% of the initial curve. There were strictly unincarcerated fully segmented hemivertebrae present in this group, 4 patients presented with intrathecal abnormalities – syringomyelia which required special care while reducing the curve during the surgery. The average intraoperative haemorrhage was 425ml and the average operating time was 3 hours. There were no neurologic alterations after the surgery. All the patients were mobilised 24-48 hours after the surgery, without any movement restrictions and were

discharged from the hospital in an average 5 days after the procedure.

4 Discussion

Scoliosis caused by hemivertebra is a progressive disease, with rapid progression and more or less unfavourable prognosis depending a few main factors: the number of hemivertebrae, the level of the deformity, the type of the hemivertebrae, the association with another congenital anomaly in the spine and the growth potential of the patient.

The most common type of hemivertebra is the fully segmented nonincurved one, also having the worst prognosis. On one side the two growth plates are absent in contrast to the opposite side with two relatively normal growth plates, this way the hemivertebra is acting like an enlarging wedge. Upper thoracic curves (T1-T4) have a slow potential for deterring, they can reach 40° at growth arrest, they usually cause an image deformity by elevating of a shoulder (it can be observed at a curve of more than 30°). Lower thoracic and thoracolumbar curves (T5-L1) have a higher deterioration rate and can exceed 45° at growth arrest. Lumbar curves (L2-L4) can also reach 45° at skeletal maturity – this way having a potential for continuous deterioration during lifetime. Lumbosacral hemivertebrae cause an oblique spinal take off which causes a large secondary structural compensatory curve above.

Royle reported in 1928 first excision of a hemivertebra using an anterior transpleural approach, Compere and VonLackum and Smith in the lumbar spine. Two stage procedures were reported and became common in practice until the next stage – single surgery with double approach by Kokubun and Leatherman.

Combined approaches offer several advantages over posterior only correction, by obtaining a better correction, reducing the potential of the crankshaft effect and the risk of the pseudarthrosis but all these the complexity, morbidity and complications of double approaches remain an important concern [12], this way leading to the development of single stage posterior surgical techniques.

Ginsburg et al reported a transpedicular hemiepifysiodesis, using a short segmentary

fixation only on the convex side, allowing correction for the patients with marked growth potential present. [13]

Our technique, using the pedicle as a passageway to the hemivertebra body, removing the cancellous bone inside it -and by this reducing the growth potential of the hemivertebra (the blood supply of the endplate comes from the cancellous bone inside the vertebral body) [14] associated with the removal of the pedicle afterwards insures that the forces developed on the convex side of the curvature will be reduced. One of the advantages of the technique is that there is no need to open the spinal canal. We stabilise the spine with pedicle screws, this system allows for better correction of the deformity using compression manoeuvres on the convex side and distraction in the concavity.

In this study we present our experience with the described surgical technique, as we managed to obtain a mean correction of about 58% of the initial curve, with only one postoperative complication which was solved at the first revision. Using the data presented in this small group we consider this a safe technique used by an experienced surgeon, offering good results and a small complications rate.

The crankshaft phenomenon did not occur in our cases as all the patients were in the Risser +++ stage, with not a very large growth potential available.

5 Conclusion

Transpedicular enucleation associated with posterior spinal fusion is a safe and effective method for one-stage correction of a spinal deformity caused by the presence of a hemivertebra. The described method allows for immediate correction of the deformity by removal of the cancellous content of the hemivertebra, thus reducing the growth potential, removal of the pedicle in some cases and direct correction with the instrumented spinal fusion by compression and distraction., reducing the growth potential and direct correction with the instrumented spinal fusion.

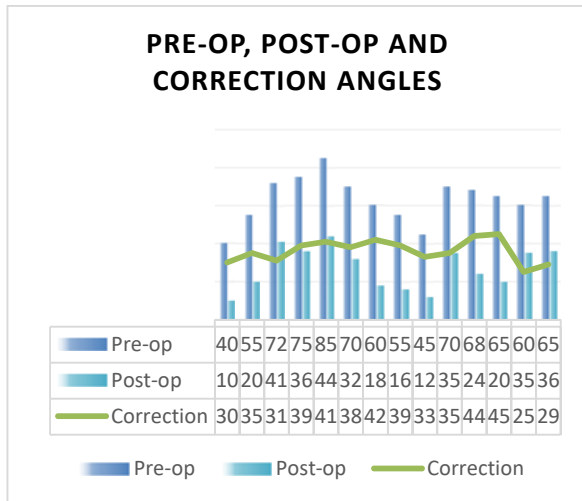


Figure 1 - Graphic view of the corrections obtained

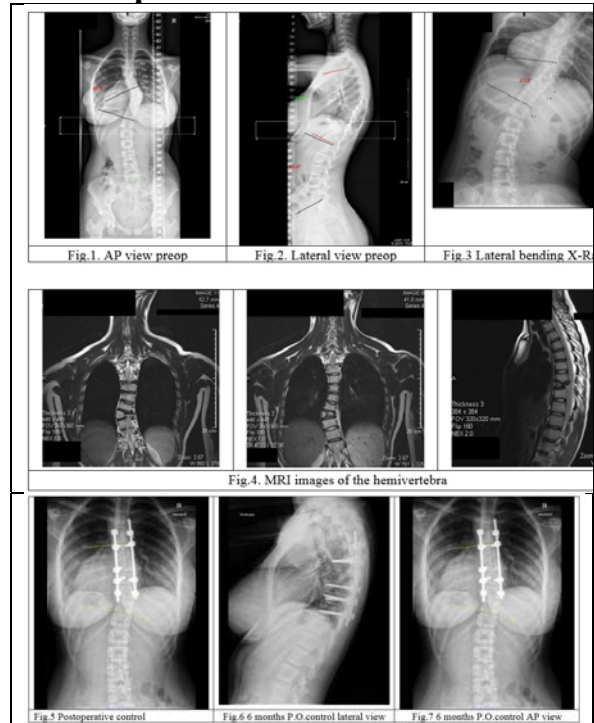
Table 1 - Details of the patients in the study group

Case	Age (yrs)	Gen.	Foll.up months	Level of Hem.	Fusion lev.	Blood loss (ml)
1	12	M	15	T7	T5-T9	200
2	14	F	12	T8	T5-T10	400
3	18	F	48	L1	T11-L2	700
4	17	M	48	T12	T4-L3	500
5	17	M	120	T10	T3-L2	500
6	18	F	84	T11	T4-L3	600
7	14	F	96	T8	T5-T11	300
8	14	F	60	T10	T8-L1	350
9	12	M	24	T7	T4-T10	200
10	13	F	60	T10	T4-L3	500
11	13	F	36	T7	T4-T11	400
12	14	M	36	T10	T4-L1	300
13	15	F	36	T6	T4-T12	400
14	16	F	24	L5	L3-S1	600

Table 2 - Radiological measurements of the patients in the study group

Case	Age (yrs)	Gen	Preop	Postop	Corr. (degr)	% Corr	Foll-up
1	12	M	40	10	30	75	15
2	14	F	43	14	29	67	12
3	18	F	72	41	31	43	48
4	17	M	75	36	39	52	48
5	17	M	85	44	41	48	120
6	18	F	70	32	38	54	84
7	14	F	60	18	42	70	96
8	14	F	55	16	39	71	60
9	12	M	45	12	33	73	24
10	17	F	70	35	35	50	60
11	13	F	68	24	44	64	36
12	14	M	65	20	45	69	36
13	15	F	60	35	25	42	36
14	16	F	65	36	29	44	24

6 Example case



E.M.L 16 years old female, T8 hemivertebra with a progressive scoliotic deformity. We performed a single stage posterior approach, enucleated the hemivertebra and corrected and stabilized the deformity with segmentary fixation.

References

- [1] Kuang Zhengda, Wang GuanJun, Ye Qibin, Ji Huiru, Zhang Xinyu, Du Mingkui, "Combination of transpedicular enucleation and Plate-Rod System for," *Acta Orthop. Belg.* vol. 82, pp. 429-433, 2016.
- [2] RN, Hensinger, "Congenital scoliosis Aetiology and Associations," *Spine*, vol. 34(17), pp. 1745-1750., 2009.
- [3] Debnath UK, Goel V, Harshavardhana N, Webb JK, "Congenital scoliosis - Quo vadiz," *Indian J Orthop*, vol. 44(2), pp. 137-147, 2010.
- [4] Winter RB, Moe JH, Lonstein JE, "A review of family histories in patients," *Orthop Trans*, p. 7:32, 1983.
- [5] Ye QB, Wang YP, Zhang J, Weng XS., "A new spinal instrumentation without fusion for

- the treatment of progressive idiopathic scoliosis in growing children.," *J Musculoskel Res*, vol. 7, pp. 201-209, 2003.
- [6] Keller DM, Lindseth RE, Derosa GP, "Progressive congenital scoliosis treatment using a transpedicular," *Spine*, pp. 1933-1939, 1994.
- [7] Alexandru Drghici, Traian Ursu, Ioan-Cristian Stoica And Dinu Antonescu, "Using the pedicle subtraction osteotomy for the corection of sagittal imbalance in spine," *PROCEEDINGS OF THE ROMANIAN ACADEMY Series B: Chemistry, Life Sciences and Geoscience*, vol. Supplement 1/2015, 2015
- [8] Andreas Eggspuehler, Martin A. Sutter, Dieter Grob, Dezso Jeszenszky, Jiri Dvorak, "Multimodal intraoperative monitoring during surgery of spinal deformities in 217 patients," *Eur Spine J*, vol. 16 (Suppl 2), p. S188-S196, 2007.
- [9] Shengru Wang, Jianguo Zhang, Guixing Qiu, Shugang Li, Bin Yu, Xisheng Weng, "Posterior hemivertebra resection with bisegmental fusion for congenital scoliosis: more than 3 year outcomes and analysis of unanticipated surgeries," *Eur Spine J*, vol. 22, p. 387-393, 2013.
- [10] Claudio Lamartina, Pedro Berjano, Mary Petruzzi, Aldo Sinigaglia, Giovanni Casero, Riccardo Cecchinato, Marco Damilano, Roberto Bassani, "Criteria to restore the sagittal balance in deformity and degenerative spondylolisthesis," *Eur Spine J*, vol. 21 (Suppl 1), p. S27-S31, 2012.
- [11] Le Huec, JC., Faundez, A., Dominguez, D. et al. , "Evidence showing the relationship between sagittal balance and clinical outcomes in surgical treatment of degenerative spinal diseases: a literature review," *International Orthopaedics (SICOT)*, vol. 39, pp. 87-95, 2015.
- [12] Wang L, Song Y, Pei F, et al, "Comparison of one-stage anteroposterior and posterior-alone hemivertebrae resection combined with posterior correction for hemivertebrae deformity," *Indian J Orthop*, vol. 45, pp. 492-499, 2011.
- [13] Ginsburg G, Mulconrey DS, Browdy J. , "Transpedicular hemiepiphysiodesis and posterior instrumentation as a," *J Pediatr Orthop*, vol. 27, pp. 387-391, 2007.
- [14] Mikles M, Graginano G, Hensinger R. , "Transpedicular eggshell osteotomies for congenital scoliosis using frameless stereotactic guidance.," *Spine*, vol. 26, pp. 2289-2296, 2001.
- [15] Franti E, Milea L, Dascalu M, Moga M. Florea C, Barbilian A, Teodorescu M, Schiopu P, Lazo F, Pogarasteanu ME, Mikles M, Graginano G, Hensinger R. , "Personalized Support System for the Patients with Forearm Amputations" *Romanian Journal of Information Science and Technology*, vol. 15, No. 4, 2012, pp. 368-376 .
- [16] Franti E, Milea L, Butu V, Cismas S, Lungu M, Schiopu P, Barbilian A, Plavitu A, "Methods of Acquisition and Signal Processing for Myoelectric Control of Artificial Arms", *Romanian Journal of Information Science and Technology*, vol. 15, No. 4, 2012, pp. 91-105.
- [17] Osiceanu S, Dascalu M, Franti E, et.al, "Intelligent Interfaces for Locomotory Prosthesis", *IJCNN: 2009 International Joint Conference on Neural Networks*